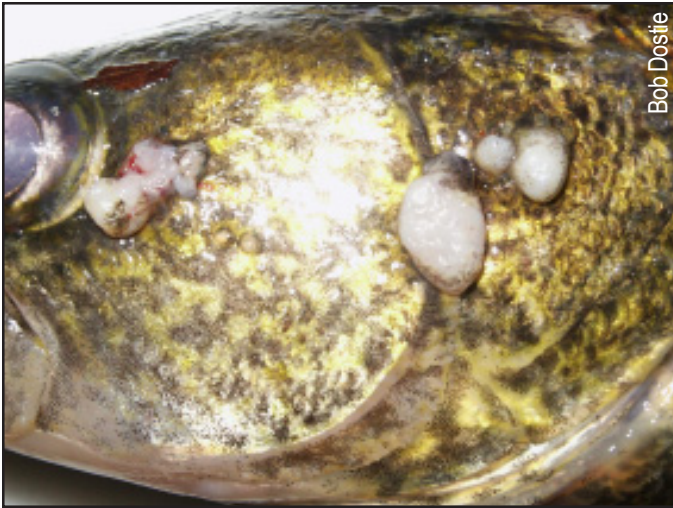

Bob Dostie

Viral warts growing on an adult walleye



Lymphocystis and Walleye Dermal Sarcoma

Often referred to as warts or tumors, Lymphocystis and Walleye Dermal Sarcoma are virus-caused diseases of fishes.

Lymphocystis is recognized worldwide in many species of freshwater and marine fishes. In Vermont, Lymphocystis is most commonly documented in adult walleye.

Walleye Dermal Sarcoma also has been documented in Vermont. It is commonly seen

on adult walleye from the Great Lakes regions of the United States and from central and western regions of Canada.

VERMONT FISH HEALTH FACT SHEET

Physical Description

Lymphocystis and Walleye Dermal Sarcoma produce warty growths commonly seen on the fish's skin and fins. Both diseases can affect the same fish at the same time. Growths are usually white to gray-white or pinkish in color. A definitive diagnosis requires microscopic examination.

Life Cycle

In walleye populations, these diseases are more common in sexually mature adults. Infections have been observed throughout the year but occur at a higher rate in early spring, during the walleye's spawning

season. Walleyes congregate on their spawning grounds, and the virus spreads from fish to fish through physical contact or water transmission.


Threat to Fish

Lymphocystis and Walleye Dermal Sarcoma infections usually are not fatal to fish.

Secondary bacterial and fungal infections can develop at sites of dislodged growths. There is no practical control of this disease in the natural environment.

Threat to Humans

These two diseases are not known to infect humans.



Walleye

VERMONT FISH & WILDLIFE DEPARTMENT

1 National Life Drive, Montpelier VT 05620-3702 (802) 828-1000 www.vtfishandwildlife.com